



Today's Date: _____
Patient Name: _____
Patient DOB: _____

SURGEON/DATE

Paul F. Cacchillo, MD
Patrick B. Hopen, MD
Anthony J. Lombardo, MD, PhD
Michael G. Orr, MD
RT _____ LT _____

SUBJECTIVE

Thrilled with visual improvement
Eye discomfort or pain
Vision improving
Vision getting worse
No complaints
Other _____

Day 1 after surgery
1 week between eyes
2-4 weeks after surgery
100 day check (refractive)

EYE MEDICATIONS

RT none Pred-Moxi-Nepaf tid x 1 week then bid x 3 weeks
LT none Pred-Moxi-Nepaf tid x 1 week then bid x 3 weeks
ofloxacin qid Durezol bid Ilevro qd

EXAMINATION

Vsc Near Vsc IOP REFRACTION
RT 20/_____ RT J_____ RT _____mmHg RT _____ 20/_____
LT 20/_____ LT J_____ LT _____mmHg LT _____ 20/_____

CONJUNCTIVA

RT white
RT mild injection
RT subconj heme
RT other

CORNEA

RT clear
RT arcuate incision(s)
RT edema
RT other

ANTERIOR CHAMBER

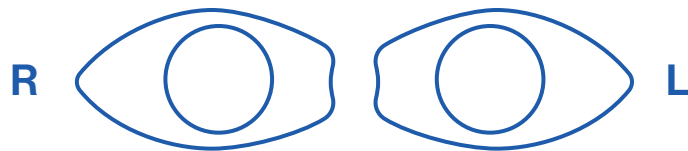
RT deep & quiet
RT mild debris
RT mild cell
RT other

IRIS

RT pupil round
RT other

IOL

RT centered & normal
RT other



POSTERIOR CAPSULE

RT clear
RT fibrosis
RT pearls
RT other

RETINA

RT unchanged
RT CME
RT other

IMPRESSION

Normal post-operative course
Other _____

PLAN

CPM and next visit in _____ week(s) / month(s) / year
Change management _____

CO-MANAGING DOCTOR (PLEASE PRINT)

Please fax to (317) 579.7435 or email to referrals@esi-in.com

Table with 4 columns: INDIANAPOLIS, GREENFIELD, ANDERSON, GREENWOOD. Includes addresses and phone numbers for each location.