



Today's Date: _____

Patient Name: _____

Patient DOB: _____

SURGEON/DATE

- Paul Cacchillo, MD
 - Patrick Hopen, MD
 - Anthony Lombardo, MD, PhD
 - Michael Orr, MD
 - Ahmar Sajjad, MD
- OD _____ OS _____

SUBJECTIVE

- Thrilled with visual improvement
- Eye discomfort or pain
- Vision improving
- Vision getting worse
- No complaints
- Other _____

- Day 1 after surgery
- 1 week between eyes
- 2-4 weeks after surgery
- 100 day check (refractive)
- _____

EYE MEDICATIONS

- OD none Pred-Moxi-Nepaf tid x 1 week then bid x 3 weeks
- OS none Pred-Moxi-Nepaf tid x 1 week then bid x 3 weeks
- ofloxacin qid
- ofloxacin qid
- Durezol bid
- Durezol bid
- Ilevro qd
- Ilevro qd
- _____
- _____

EXAMINATION

Vsc	Near Vsc	IOP	REFRACTION
OD 20/____	OD J____	OD ____mmHg	OD _____ 20/____
OS 20/____	OS J____	OS ____mmHg	OS _____ 20/____

CONJUNCTIVA

- OD OS
- white
 - mild injection
 - subconj heme
 - other

CORNEA

- OD OS
- clear
 - arcuate incision(s)
 - edema
 - other

ANTERIOR CHAMBER

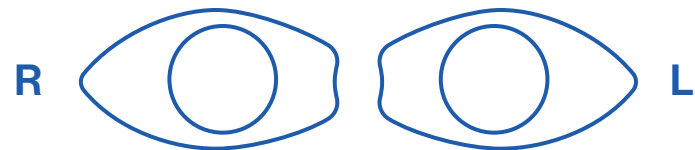
- OD OS
- deep & quiet
 - mild debris
 - mild cell
 - other

IRIS

- OD OS
- pupil round
 - other

IOL

- OD OS
- centered & normal
 - other



POSTERIOR CAPSULE

- OD OS
- clear
 - fibrosis
 - pearls
 - other

RETINA

- OD OS
- unchanged
 - CME
 - other

IMPRESSION

- Normal post-operative course
- Other _____

PLAN

- CPM and next visit in _____ week(s) / month(s) / year
- Change management _____

CO-MANAGING DOCTOR (PLEASE PRINT)

Please fax to (317) 579.7435 or email to referrals@esi-in.com