



Today's Date: \_\_\_\_\_

Patient Name: \_\_\_\_\_

Patient DOB: \_\_\_\_\_

SURGEON/DATE

Paul F. Cacchillo, MD

Patrick B. Hopen, MD

Anthony J. Lombardo, MD, PhD

Michael G. Orr, MD

RT \_\_\_\_\_

LT \_\_\_\_\_

SUBJECTIVE

- Thrilled with visual improvement
 Eye discomfort or pain

- Vision improving
 Vision getting worse

- No complaints
 Other \_\_\_\_\_

- Day 1 after surgery
 1 week between eyes
 2-4 weeks after surgery
 100 day check (refractive)
 \_\_\_\_\_

EYE MEDICATIONS

- RT  none  Pred-Moxi-Nepaf tid x 1 week then bid x 3 weeks
 LT  none  Pred-Moxi-Nepaf tid x 1 week then bid x 3 weeks

- ofloxacin qid  Durezol bid  Ilevro qd  \_\_\_\_\_
 ofloxacin qid  Durezol bid  Ilevro qd  \_\_\_\_\_

EXAMINATION

Vsc

RT 20/\_\_\_\_
LT 20/\_\_\_\_

Near Vsc

RT J\_\_\_\_
LT J\_\_\_\_

IOP

RT \_\_\_\_mmHg
LT \_\_\_\_mmHg

REFRACTION

RT \_\_\_\_\_ 20/\_\_\_\_
LT \_\_\_\_\_ 20/\_\_\_\_

CONJUNCTIVA

- RT LT
  white
  mild injection
  subconj heme
  other

CORNEA

- RT LT
  clear
  arcuate incision(s)
  edema
  other

ANTERIOR CHAMBER

- RT LT
  deep & quiet
  mild debris
  mild cell
  other

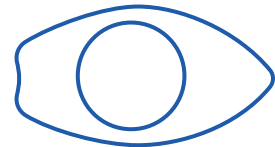
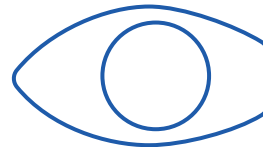
IRIS

- RT LT
  pupil round
  other

IOL

- RT LT
  centered & normal
  other

R



L

POSTERIOR CAPSULE

- RT LT
  clear
  fibrosis
  pearls
  other

RETINA

- RT LT
  unchanged
  CME
  other

IMPRESSION

- Normal post-operative course
 Other \_\_\_\_\_

PLAN

- CPM and next visit in \_\_\_\_\_ week(s) / month(s) / year
 Change management \_\_\_\_\_

CO-MANAGING DOCTOR (PLEASE PRINT)

Please fax to (317) 579.7435 or email to referrals@esi-in.com

INDIANAPOLIS

9202 N. Meridian St., Suite 100 Indianapolis, IN 46260 (317) 841.2020

GREENFIELD

740 W. Green Meadows Dr., Suite 310 Greenfield, IN 46140 (317) 462.2020

ANDERSON

1603 S. Scatterfield Rd. Anderson, IN 46016 (765) 644.2020

GREENWOOD

533 E. County Line Rd., Suite 210 Greenwood, IN 46143 (317) 882.2015